

LOCALIZATION OF DIFFERENT LYMPHOCYTE'S POPULATION IN THE SPLEEN, WHICH WERE DETECTED BY MONOCLONAL ANTIBODIES

The detailed studies of immunoarchitektony and cytoarchitecture of the immune system normally necessary in connection with the development and creation of new immunomodulators and new generations of antibiotics for preclinical testing which necessarily requires the morphological and immunohistochemical analysis of structural and functional changes in the lymphoid organs of laboratory animals.

Keywords: immunohistochemistry, spleen.

Nowadays there are two basic methods of leucocytes' subunit's immunophenotyping - flow cytometry and immunohistochemistry (IHC)

The advantage of IHC over flow cytometry is the fact, that objects of investigation can be analyzed retrospectively, because the material which was fixed in formalin and filled with paraffin can be used after finishing of some parts of investigations. It is very important because earlier IHC investigations were making only on frizzed cryostat section, were the safety of antigenic epitopes suffered noticeably. (K.J. Randall, G. Pearce, 2008).

The investigation's purpose - to detect the cytoarchitektony features of white pulp's T- and B- cellular compartments in the rat's spleen.

Material and methods. The investigation was made at the six sexually mature rats. The serial paraffin slices of the spleen, fixed in formalin, with the width 5 mcm were colored by immunohistochemical monoclonal antibodies against CD1a, CD3, CD4, CD8, CD 20, CD23, and also by myeloperoxidase for detecting neutrophils and eosinophils.

The unmasking was in the buffer with pH 9.0 in the apparatus PT LINK DAKO, during 20 minutes. The reaction's setting was in Autostainer Link 48 DAKO with using systems of visualization En Vision Flex+Mouse (Link). The tint - En Vision flex hematoxylin.

Dehydration was in three changes of ethanol and the enlightenment in the O-xilol.

The conclusion was in the integumentary environment MOUNT-QUICK. The slices were colored by hematoxylin and eosin for control.

Results: The white pulp of the mammalian spleen is divided into lymphoid periarterial clutches, lymphoid nodules and marginal zone.

As distinct from spleen of human and mammals, for rats spleen characteristically clearly distinguished, when stained with hematoxylin and eosin and Giemsa or hematoxylin-II-eosin sections of white pulp - B- and T- dependent zone mantle zone (crown) and also marginal sinus and marginal zone.

On sections CD1a positive cells with intense antigen-antibody reaction, and localized in the membranes in the cytoplasm, revealed in the subcapsular zone of the periphery of the body of the spleen. They were presented with large cells round, oval or polygonal shape with eccentrically arranged nuclei, and with many branched processes on the membrane ("dendrite cells")

The vast majority of cells forming periarterial lymphoid clutches displayed a positive response to CD3, high density of that cells observed along inner margin of PALM closer to wall of central artery.

Identification of CD4+ cells using antibodies MoAb (SP35) showed that all of the T-helper expressed with the antigen-antibody reaction on the membranes located at the outer edge of the marginal zone at the interface with red pulp.

CD8+ (T-NK marker), detected using an antibody MoAb (SP16) observed in the form of individual clusters in the red pulp. Antigen-antibody reaction, localized in the membranes as well as in the cytoplasm, revealed a high staining intensity from brown to black. Particularly high intensity of the reaction of CD8+ cells was observed along the venous sinuses of the red pulp forming cruciform plexus, the so-called "crisscross vessels".

In carrying out the reaction using antibody MoAb (SP32) detected on CD20 + a clear antigen-antibody reaction in the form of intense coloration membranes of mature B-lymphocytes in a large amount, a high bulk density in the filling zone and the marginal zone of lymphoid nodules (Fig.1).

CD23+ follicular dendritic cells and germinal centers identified using antibodies MoAb (SP23), were observed in the red pulp in only one case, as the spherical shape of a single cluster as a unit in the center of the emerging lymphoid nodules (Fig 2).

The reaction to myeloperoxidase antibody MoAb (SP 72), dyeing, neutrophils and eosinophils, revealed the presence of a considerable amount of peripheral blood in the vessel lumen. Whereas organ's parenchyma, which located between lymphoid nodules, spleen revealed only a few, intensely colored from dark brown to black, neutrophils and eosinophils.

Thus, various lymphocyte populations are distinct in their specific location of the multi-splenic parenchyma

Conclusions: 1. Lymphocyte's different populations have a distinct localization in the spleen's parenchyma.

2. IHC let us to detect not only lymphocyte's phenotype, but theirs' functional condition.

3. The spleen's parenchyma has an expressed zonal features of structure.

4. Immunophenotyping of lymphocyte's T- and B- cellular compartments by using IHC method confirms the hypothesis of "Krieken", about the fact, that every zone of the spleen (camera) has an own unique structure and function.

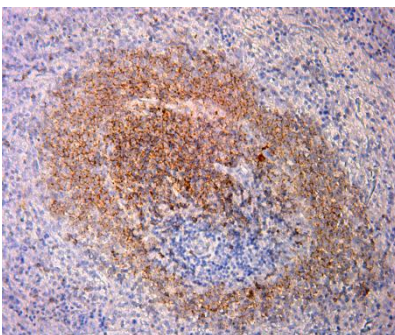


Figure 1 - Spleen of the rat. CD20 + lymphocytes

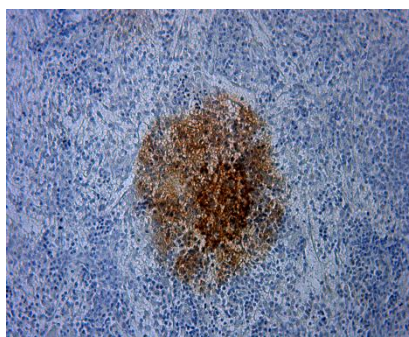


Figure 2 - Splenoferat. CD23+lymphocytes

REFERENCES

- 1 K.J. Randall, G. Pearse. A dual-label technique for the immunohistochemical demonstration of T-lymphocyte subsets in formalin-fixed, paraffin-embedded rat lymphoid tissue//Toxicologic Pathology.-2008.-36.-795-804

Т.М.ДОСАЕВ, А.МАЙДАН, Д.БАКТЫБАЕВ

МОНОКЛОНДЫ АНТИДЕНЕ АРҚЫЛЫ КӨКБАУЫРДА АНЫҚТАЛҒАН ӘРТҮРЛІ ТЕКТІ ЛИМФОЦИТТЕРДІҢ ШОҒЫРЛАРЫ

Түйін:Моноклонды антиденелермен иммуногистохимиялық тәсіл арқылы CD1a, CD3, CD4, CD8, CD20, CD23-ге қарсы көкбауыр паренхимасының иммуноархитектоникасы зерттелді. Көкбауырдың көп бөлшектік паренхимасында әртүрлі текті лимфоцит топтарының орналасуларының өздерінің айқын анықталған заңдылығы бар екендігі белгілі болды.

Түйінді сөздер:иммуногистохимиялық тәсіл, көкбауыр.

Т.М.ДОСАЕВ, А.МАЙДАН, Д.БАКТЫБАЕВ

**ЛОКАЛИЗАЦИЯ РАЗЛИЧНЫХ ПОПУЛЯЦИЙ ЛИМФОЦИТОВ
В СЕЛЕЗЕНКЕ, ВЫЯВЛЕННЫХ С ПОМОЩЬЮ МОНОКЛОНАЛЬНЫХ АНТИТЕЛ**

Резюме: Методом иммуногистохимии моноклональными антителами против CD1a, CD3, CD4, CD8, CD20, CD23 была изучена иммуноархитектоника паренхимы селезенки. Установлено, что различные популяции лимфоцитов имеют четко выраженную закономерную локализацию в многокамерной паренхиме селезенки.

Ключевые слова: иммуногистохимия, селезенка.